

RESEARCH

Open Access



A direct referencing method of the tibial plateau for the posterior tibial slope in medial unicompartmental knee arthroplasty

Masao Akagi^{1,2*}, Hisafumi Aya², Shigeshi Mori³, Nobuhisa Syogaku², Ichiro Tsukamoto¹ and Akihiro Moritake¹

Abstract

Purpose: There is no consensus on intraoperative references for the posterior tibial slope (PTS) in medial unicompartmental knee arthroplasty (UKA). An arthroscopic hook probe placed on the medial second quarter of the medial tibial plateau (MTP) in an anteroposterior direction may be used as a direct anatomical reference for the PTS. The purpose of this study is to investigate the availability and accuracy of this method.

Methods: Marginal osteophyte formation and subchondral depression of the MTP and angles between the bony MTP and the cartilage MTP were retrospectively evaluated using preoperative sagittal MRI of 73 knees undergoing medial UKA. In another 36 knees, intraoperative lateral knee radiographs with the probe placed on the MTP were prospectively taken in addition to the preoperative MRI. Then, angles between the bony MTP and the probe axis and angles between the preoperative bony MTP and the postoperative implant MTP were measured.

Results: Among 73 knees, one knee with grade 4 osteoarthritis had a posterior osteophyte higher than the most prominent point of the cartilage MTP. No subchondral depression affected the direct reference of the MTP. The mean angle between the bony MTP and the cartilage MTP was $-0.8^\circ \pm 0.7^\circ$ (-2.6° – 1.0° , $n = 72$), excluding one knee with a “high” osteophyte. The mean angle between the bony MTP and the probe axis on the intraoperative radiograph was $-0.6^\circ \pm 0.4^\circ$ (-1.7° – 0.0° , $n = 36$). The mean angle between the pre- and postoperative MTP was $-0.5^\circ \pm 1.5^\circ$ (-2.9° – 1.8°). The root-mean-square (RMS) error of these two PTS angles was 1.6° with this method.

Conclusion: Cartilage remnants, osteophyte formation and subchondral bone depression do not affect the direct referencing method in almost all knees for which medial UKA is indicated. When the posterior “high” osteophyte of the MTP is noted on preoperative radiography, preoperative MRI or CT scan is recommended to confirm no “high” osteophyte on the medial second quarter. The accuracy of this method seems equal to that of robotic-assisted surgery (the RMS error in previous reports, 1.6° – 1.9°).

Keywords: A direct referencing method, Medial tibial plateau, Posterior tibial slope, Medial unicompartmental knee arthroplasty, Availability, Accuracy

Introduction

Recently, medial unicompartmental knee arthroplasty (UKA) has been recognized as an excellent treatment option for progressive medial knee osteoarthritis (OA) [1–4]. Knee function and patient satisfaction have been reported to be favorably comparable to total knee arthroplasty [5–7]. The functional superiority of medial UKA with nearly normal kinematics is attributable to

*Correspondence: makagi@med.kindai.ac.jp

¹ Department of Orthopaedic Surgery, Kindai University Hospital, 377-2 Ohno-Higashi, Osaka-Sayama City, Osaka 589-8511, Japan
Full list of author information is available at the end of the article



© The Author(s) 2022. **Open Access** This article is licensed under a Creative Commons Attribution 4.0 International License, which permits use, sharing, adaptation, distribution and reproduction in any medium or format, as long as you give appropriate credit to the original author(s) and the source, provide a link to the Creative Commons licence, and indicate if changes were made. The images or other third party material in this article are included in the article's Creative Commons licence, unless indicated otherwise in a credit line to the material. If material is not included in the article's Creative Commons licence and your intended use is not permitted by statutory regulation or exceeds the permitted use, you will need to obtain permission directly from the copyright holder. To view a copy of this licence, visit <http://creativecommons.org/licenses/by/4.0/>. The Creative Commons Public Domain Dedication waiver (<http://creativecommons.org/publicdomain/zero/1.0/>) applies to the data made available in this article, unless otherwise stated in a credit line to the data.

preservation of functional knee structures, including nondisease compartments and both cruciate ligaments, and restoration of the preoperative joint surface morphology and knee alignment [8–11]. Conversely, proper implant positioning is critical for long-term survival after UKA, and malpositioning and alignment can alter the biomechanics of the knee, increasing ligament strain and contact stresses [12–14].

The posterior tibial slope (PTS) of the medial tibial plateau (MTP), defined as the posterior inclination of the plateau relative to the tibial bone axis, is considered an important anatomical feature that influences cruciate ligament function and sagittal plane stability of the knee [15–19], and wide individual variations of up to 14° have been reported in the PTS for both normal and arthritic knees [20–22]. PTS has been reported to affect implant survival [20], postoperative range of motion [19, 23], and knee kinematics after UKA [10, 24]. Therefore, accurate recreation of the preoperative PTS is critical for the optimization of postoperative knee function and longevity [20].

In the operative field of modern mini-incision UKA, however, it is difficult to observe the entire MTP, including its posterior edge, until completion of the femoral bony preparation. Recently, using preoperative CT data in patients with medial UKA, we have suggested that we refer the MTP to recreate the native PTS by placing an arthroscopic probe in the anteroposterior (AP) direction on the medial second quarter of the MTP [25]. However, deformities of the MTP associated with OA progression, including cartilage remnants and cartilaginous osteophyte formation, may make it difficult to use the MTP itself as an anatomical reference. In this study, preoperative sagittal magnetic resonance imaging (MRI) in knees undergoing medial UKA was retrospectively reviewed to evaluate the influence of OA changes on the MTP. Furthermore, intraoperative lateral knee radiographs with a hook probe placed on the MTP and postoperative lateral knee radiographs were prospectively taken. The purpose of this study is to demonstrate the availability and accuracy of the direct referencing method of the MTP in medial UKA.

Patients and methods

Patients

Study I: Preoperative MRI studies

Preoperative MRI examination of the knee is routinely performed in our institute to check the conditions of the anterior cruciate ligament (ACL), the lateral femorotibial compartment and the patellofemoral joint and to determine indications for UKA. In this study, 73 consecutive knees with primary medial UKA between June 2018 and July 2020 were included. Surgical indications for medial

UKA included medial unicompartmental knee OA, a functional ACL, correctable varus deformity and flexion deformity of <15°. Inflammatory arthritis and severe knee OA with strong destruction of the MTP and/or subluxation of the femorotibial joint were excluded from indication of medial UKA. The mean age of the patients was 76.5 ± 5.8 years (62–86), and there were 16 male and 57 female knees. The severity of OA according to the K–L classification [26] was grades 2, 3 and 4 in 13, 46 and 14 knees, respectively. The mean femorotibial angle (FTA) in the standing AP radiographs was $181.4^\circ \pm 2.7^\circ$ (175–186), and the mean preoperative PTS was $8.3^\circ \pm 1.8^\circ$ (3.4–15.4).

Study II: Intra- and postoperative lateral knee radiograph studies

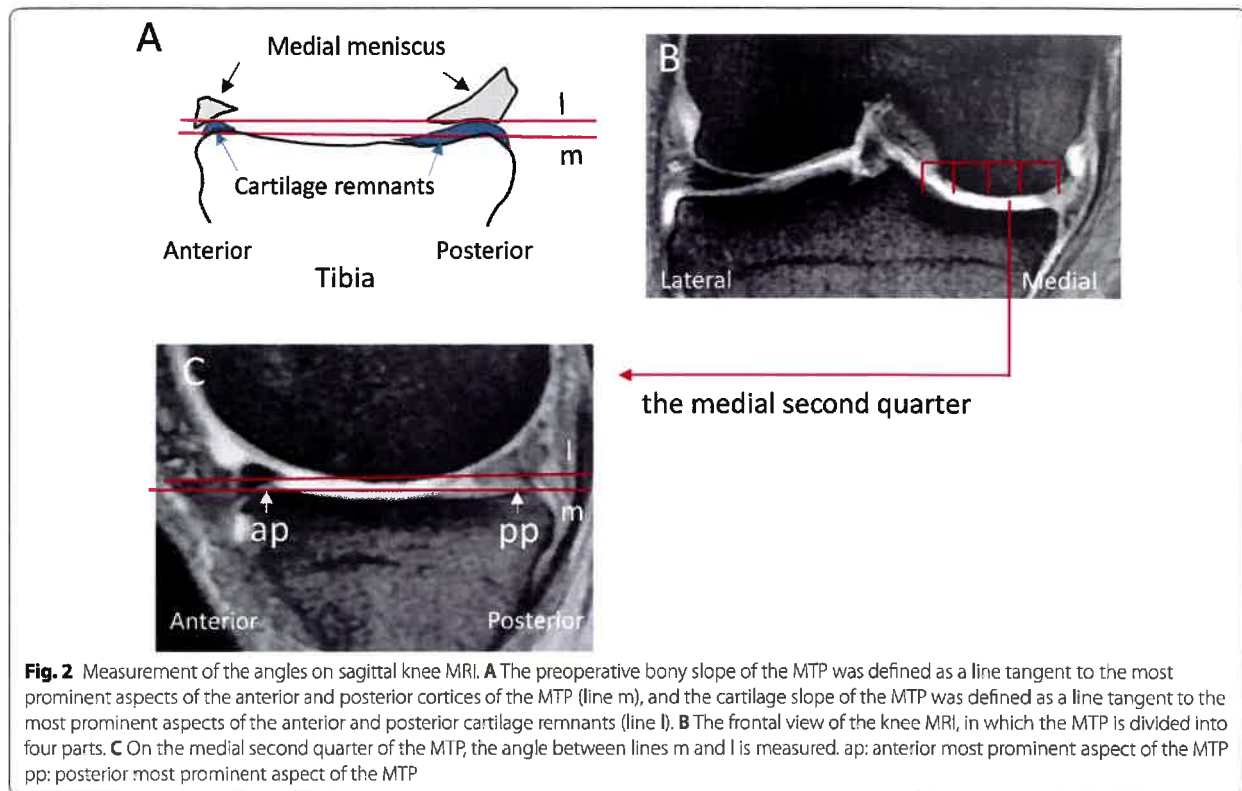
Between February 2021 and January 2022, 36 consecutive knees were considered to have indications for medial UKA and were prospectively collected to confirm the results of Study I. Preoperative MRI examination of the knee was performed for all patients as in Study I. The mean age of the patients was 75.0 ± 8.9 years (range, 48–88 years), and there were 7 male and 29 female knees. The severity of OA was grade 2, 3 and 4 in 6, 22 and 8 patients, respectively. The mean FTA on standing AP radiographs was $180.1^\circ \pm 2.6^\circ$ (177–185), and the mean PTS was $8.5 \pm 2.4^\circ$ (3.3–14.1).

Both the Study I and II protocols were approved by the Institutional Review Board, and informed consent was obtained from each patient prior to study enrollment.

Imaging technique

The knee MRI in Studies I and II was performed using a 1.5-Tesla imager (Signa HDxT, General Electric Medical Systems, Milwaukee, WI) with an eight-channel knee coil (HD TR knee phase array). The patients were positioned supine on the MRI scanning table with the knee extended and the patella facing upward. Coronal, sagittal and axial images were obtained in a standardized manner. Images were acquired according to a common standard knee MRI protocol of the Department of Radiology, which included coronal and sagittal multiple echo recalled gradient echo images for the present study (TR: Cor/Sag 800/600, each with 4 echoes). A 3.5-mm slice thickness with a 0.5-mm slice space was used.

The intraoperative lateral knee radiograph was taken using a portable X-ray machine (MobileDaRt Evolution MX8 Version, SHIMADZU, Kyoto, Japan), which has wireless flat panel detectors (FPDs, DR-ID800, FUJIFILM, Tokyo, Japan) and can show reference X-ray images on an installed monitor immediately after radiography. After arthrotomy, stripping off of the medial capsular attachment from the proximal tibia, and resection of the anterior half of the medial meniscus, an



implant (Tribrid UKA system, Kyocera Corp., Kyoto, Japan) was implanted through the medial mini-parapatellar skin incision. The operation was performed using the so-called tibia-cut first and spacer block technique. First, the substitute tibial AP line [28] was drawn to pass through the medial tibial eminence and the medial edge of the patellar tendon at the joint level. Then, an arthroscopic hook probe was placed in the AP direction on the medial second quarter of the MTP. An individual implant PTS was determined by setting a gauge inserted into the cut slot of the extramedullary guide parallel to the probe (see Fig. 7E).

Angular measurements on the intra- and postoperative lateral knee radiographs

Preoperative bony PTS (α) and postoperative implant PTS (β) on a lateral radiograph were measured according to a method previously reported [20]. A line passing through the center of 2 circles located over the AP width of the tibia was drawn (line t in Fig. 3A and B). Then, a line perpendicular to line t was drawn (line l_1). The angle between line l_1 and a line tangential to the subchondral plate of the MTP (line m_1) was measured as the preoperative bony PTS (angle α in Fig. 3A). Similarly, implant PTS was defined as an angle between a line l_2 and a line

m_2 tangential to the upper surface of the tibial tray (angle β in Fig. 3B). On the intraoperative lateral knee radiograph, the native bony MTP was defined as a line tangent to the subchondral plate of the MTP (line m_3). The cartilage slope of the MTP was defined as a line of the probe axis placed on the medial second quarter of the MTP with cartilage remnants (line l_3). The angle formed by these two lines was measured (angle γ in Fig. 3C).

Statistical analysis

The height of the osteophyte and expansion of subchondral bone depression in each knee were classified by two observers (M.A. and H.A.), upon their discussion and confirmation. All angular measurements on the sagittal MRI and lateral knee radiography were independently performed twice by two observers (S.M. and N.S.), and the mean of four measurements was considered a true value. The intraclass correlation coefficient for interrater reliability of these two observers on the MRI and on the intraoperative lateral knee radiography was 0.68 and 0.77, respectively. The results are presented as the mean \pm standard deviation (SD) and were processed using Microsoft Excel 2016 (Microsoft Corp., Redmond, WA). Differences between results were evaluated using Student's unpaired or paired *t*

arthroscopic hook probe was placed on the medial second quarter of the MTP (between the medial 1/4 and 1/2 MTP), parallel to the AP tibial line [27, 28] with the knee flexed at approximately 90°. Radiography was repeated until the correct laterality was confirmed on the monitor of the portable machine.

Evaluation of osteophyte height and expansion of subchondral bone depression in the MTP using sagittal MRI

Using sagittal MRI, we evaluated the height of the anterior/posterior osteophyte and anterior/posterior expansion of subchondral bone depression (attrition) [29] on the medial second quarter of the MTP to determine whether they can affect the MTP indicated by the arthroscopic probe placed on it. Relative to a line tangent to the most prominent aspects of the anterior and posterior cortices of the MTP including cartilage remnants (line t in Fig. 1A), osteophyte height was classified into three categories as follows: none (N), there is no osteophyte; low (L), same as or lower than the line t; and high (H), higher than line t. Based on location, expansion of the subchondral depression was classified into three categories as follows: none (N), there is no depression; moderate (M), the depression expands to the anterior or the posterior 1/3 of the MTP but does not reach the most prominent aspect of the anterior and posterior cortices;

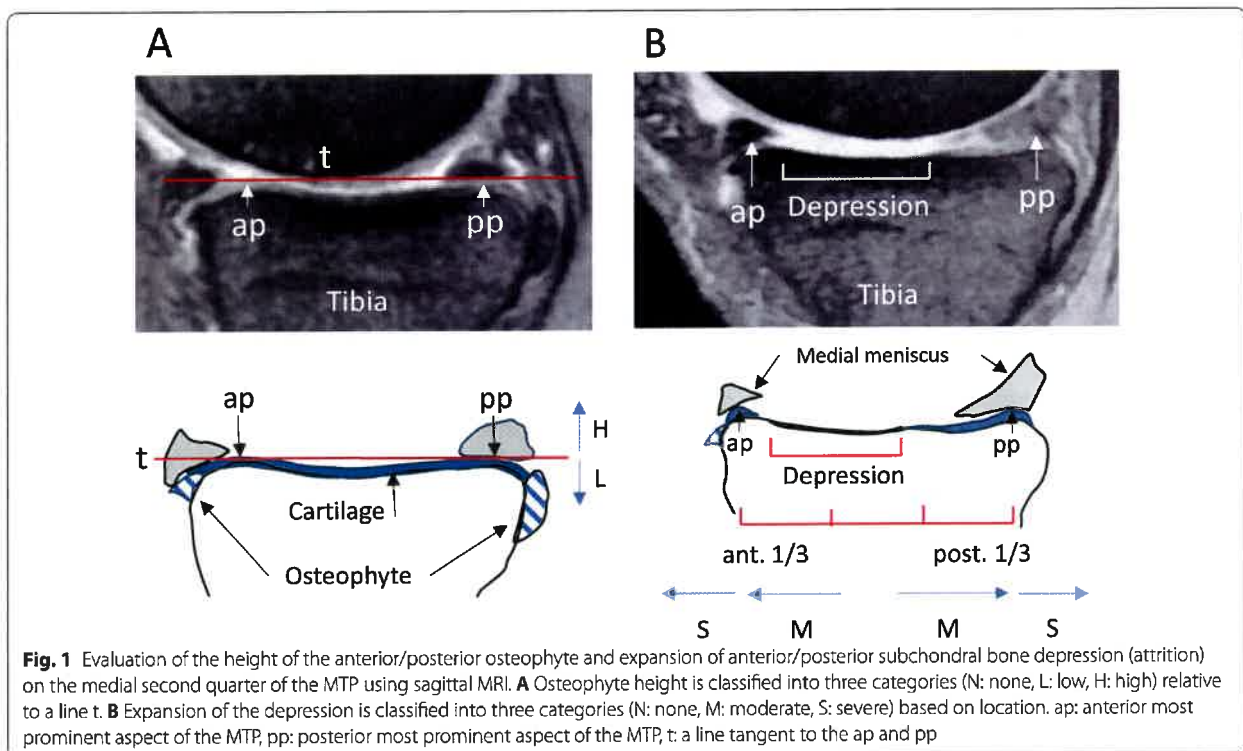
and severe (S), the depression expands to or over the most prominent aspects of the anterior or posterior cortices (Fig. 1B).

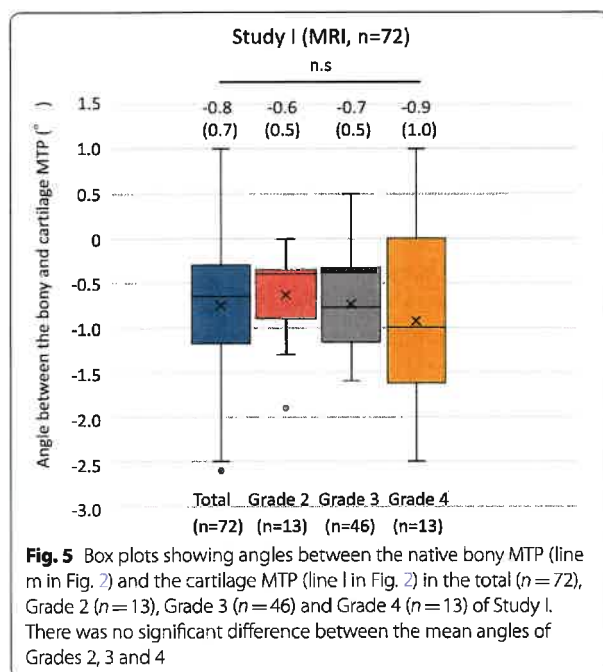
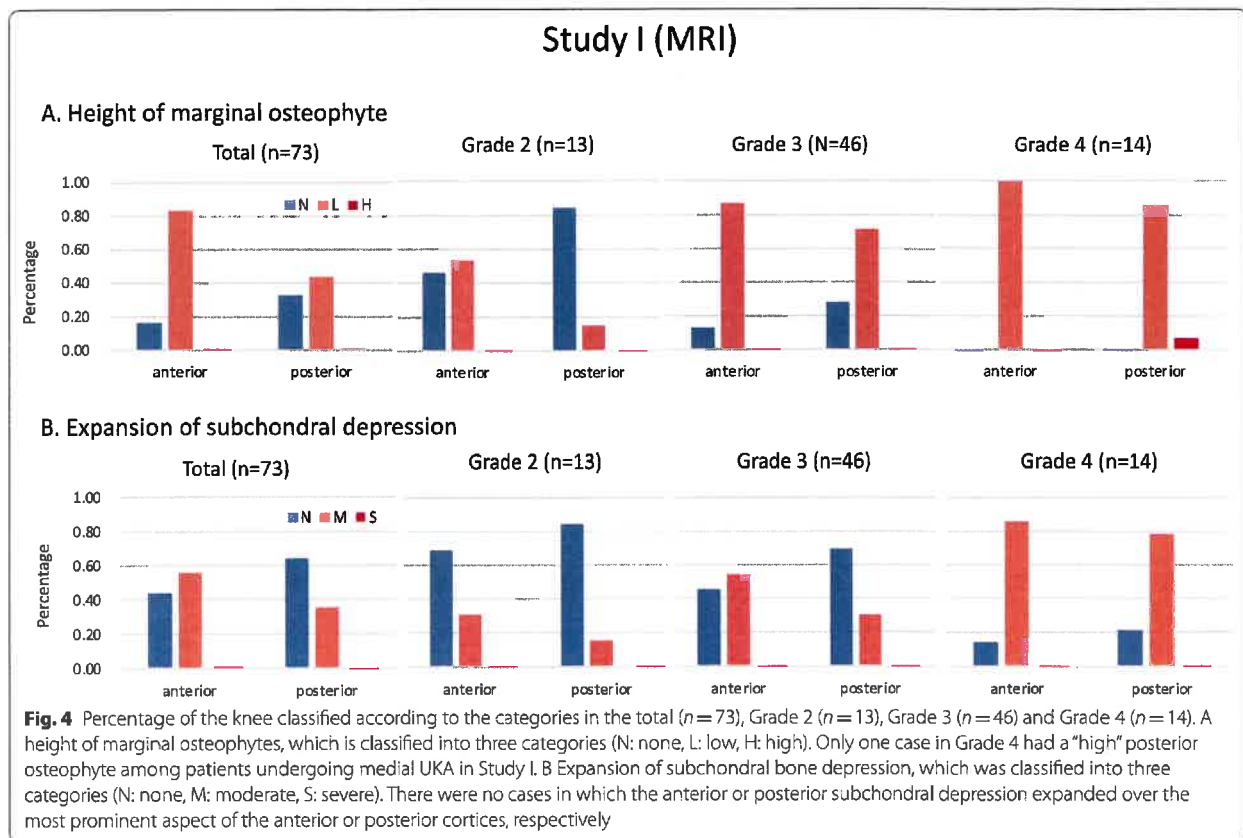
Angular measurements on sagittal MRI

The preoperative bony MTP in sagittal MRI was defined as a line tangent to the most prominent aspects of the anterior and posterior cortices (subchondral bone plate) according to methods previously described [24, 30] (line m in Fig. 2A and C). The cartilage slope of the MTP was defined as a line tangent to the most prominent aspects of the anterior and posterior cartilage remnants of the MTP (line l in Fig. 2A and C). Frontal and sagittal views of the knee MRI were simultaneously displayed on an image analysis monitor. While the frontal view showed a middle slice of the knee (Fig. 2B), a slice of the medial second quarter of the MTP (Fig. 2B) was displayed on the sagittal view. The angle formed by the two tangential lines (lines m and l) was measured on both slices using image analysis software (PACS system FABRICA Ver. 1.0.0.23, Cure Hope Corp., Osaka, Japan). A positive value was given to the angle measurement when the cartilage PTS (line l) was larger than the preoperative bony PTS (line m).

Surgical technique with the direct referencing method

All surgical procedures in Study II were performed by one senior surgeon (M.A.), and a fixed-bearing UKA

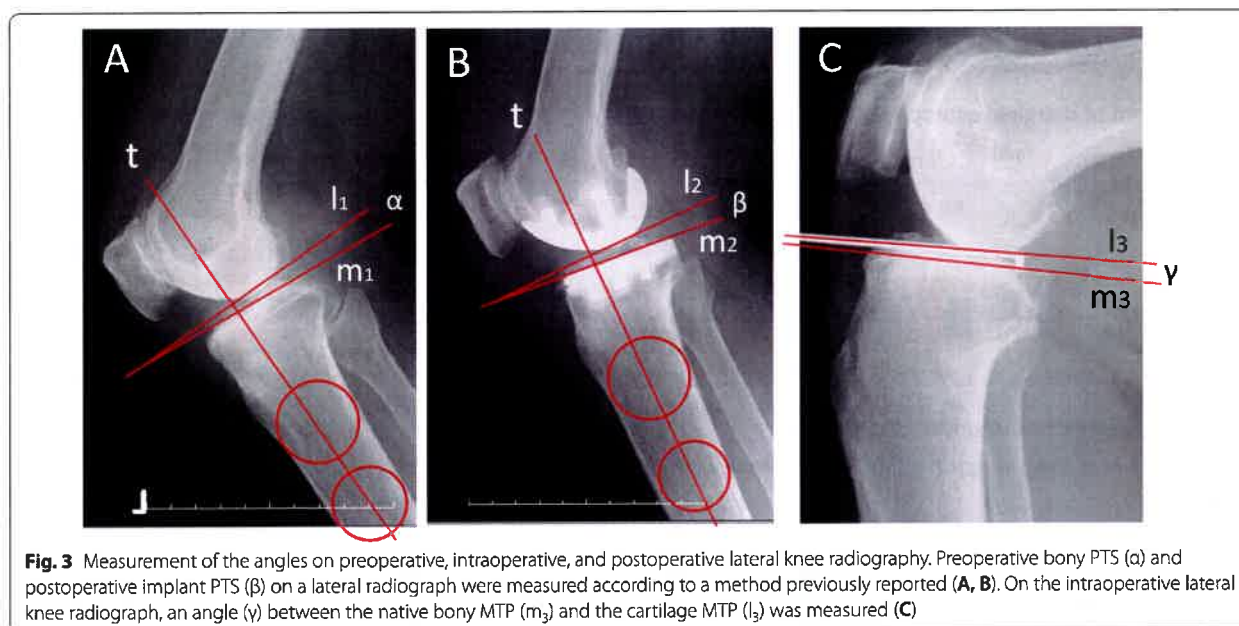




radiograph was observed ($r = 0.38$, $p < 0.05$, Fig. 6B). The mean angles of the preoperative PTS and the implant PTS were $8.5^\circ \pm 2.4$ (3.3 – 14.1) and $7.9^\circ \pm 2.2^\circ$ (3.4 – 11.6), respectively, and there was a significant difference between these mean angles ($p < 0.05$, paired t test, $n = 36$, Fig. 6C). The mean angle difference between the preoperative and implant PTS was $-0.5^\circ \pm 1.5^\circ$ (-2.8 – 1.8) (Fig. 6D). The RMS error of the tibial slope was 1.6° with this method. There was a strong correlation between the preoperative and implant PTS ($r = 0.83$, $p < 0.001$, Fig. 6E).

Case presentation

An 88-year-old male patient presented with grade 4 knee OA (Fig. 7A). Preoperative MRI showed anterior and posterior “low” osteophytes (*) and anterior and posterior “mild” depression on the MTP (Fig. 7B). A hook probe (Fig. 7C) was placed on the medial second quarter of the MTP in an AP direction. Then, an intraoperative lateral knee radiograph was taken (Fig. 7D). A gauge (g in Fig. 7E) inserted into the slot of the tibial cut block was set parallel to the probe (p in Fig. 7E). A postoperative lateral knee radiograph demonstrated that the native bony PTS was recreated (Fig. 7F).



tests. Pearson's correlational analysis was performed to analyze the relationships between the two angle measurements in Study II. The root-mean-square (RMS) error was used to evaluate the accuracy of the direct referencing method.

Results

Study I: Height of the anterior/posterior marginal osteophyte (Fig. 4A)

Eighty-four and 66% of total knees had an anterior "low" and a posterior "low" osteophyte, respectively. In 14 knees with Grade 4 OA, one knee (7%) had a "high" posterior osteophyte. Although the number of knees with anterior and/or posterior osteophytes increased with the K-L grade, the number of knees with anterior osteophytes increased from the lower grade compared with the number of knees with posterior osteophytes.

Study I: Expansion of subchondral bone depression (Fig. 4B)

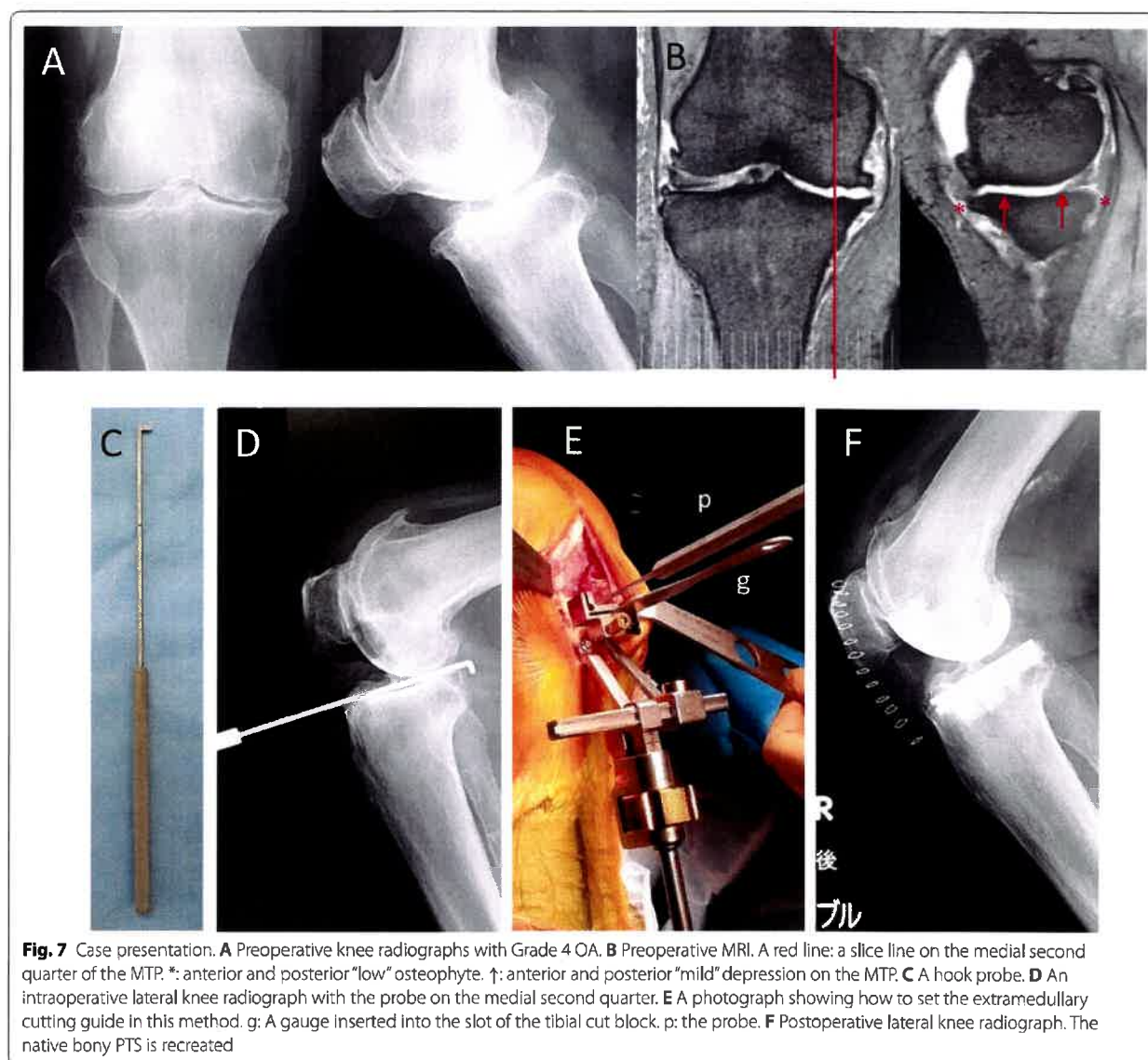
Fifty-six and 37% of the total knees had anterior "moderate" and posterior "moderate" depression, respectively. Although knees with anterior and/or posterior depression increased with the K-L grade, the number of knees with anterior depression increased from the lower grade compared with the number of knees with posterior depression. There was no knee with anterior and/or posterior "severe" depression in these 73 knees.

Angular measurements in the sagittal view of the MRI in Study I (Fig. 5)

Angular measurements were performed for all knees except for one knee with a posterior "high" osteophyte. The mean angle of the total knees between the two tangential lines (line m and line l in Fig. 2) on the sagittal view of MRI was $-0.8^\circ \pm 0.7^\circ$ (-2.6° – -1.0° , $n=72$). There was no significant difference between the mean angle in Grade 2 ($-0.6^\circ \pm 0.5^\circ$, -1.9° – -0.0° , $n=13$), Grade 3 ($-0.7^\circ \pm 0.5^\circ$, -1.6° – -0.5° , $n=46$), and Grade 4 ($-0.9^\circ \pm 1.1^\circ$, -2.5° – -1.0° , $n=13$) (Fig. 5). The angle between the two tangential lines in one knee with the posterior "high" osteophyte was 3.2 degrees.

Angular measurements on the preoperative sagittal MRI and on the intra- and postoperative lateral knee radiographs in Study II

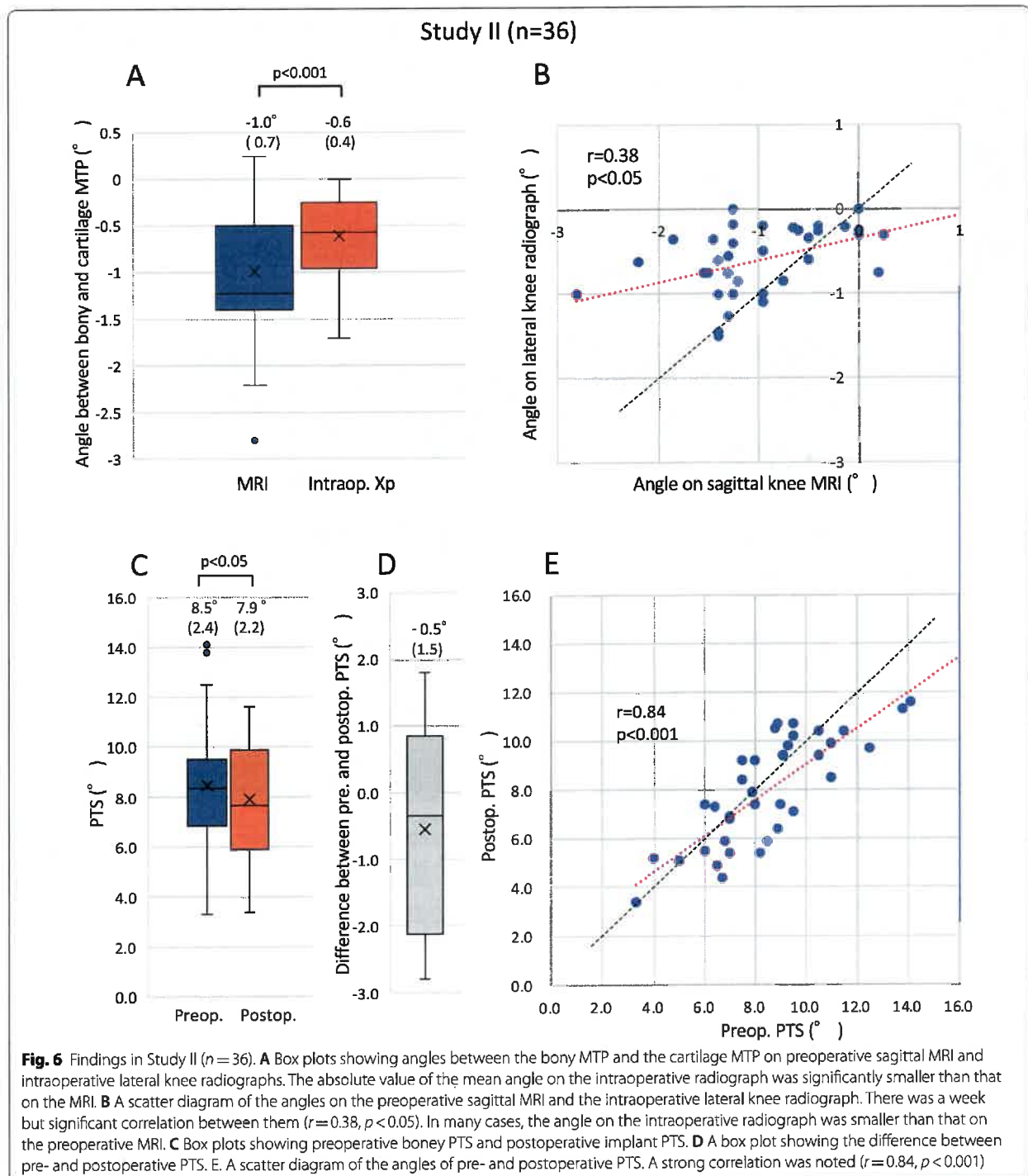
There was no knee with anterior and/or posterior "high" osteophytes in Study II. Furthermore, there was no knee with anterior and/or posterior "severe" depression. The mean angle between the two tangential lines (lines m and l in Fig. 2) on the preoperative sagittal MRI was $-1.0^\circ \pm 0.7^\circ$ (-2.8 – -0.3 , $n=36$). The mean angle between the probe axis and the bony MTP on the intraoperative lateral knee radiograph (lines m_3 and l_3 in Fig. 3C) was $-0.6^\circ \pm 0.4^\circ$ (-1.7 – -0.0 , $n=36$). The mean angle on the intraoperative lateral knee radiograph was smaller than that on the sagittal MRI ($p < 0.001$, paired t test, $n=36$, Fig. 6A). A weak but significant correlation between the angles on the sagittal MRI and on the lateral knee



the most prominent aspect of the cartilage MTP were observed near the posterior cruciate ligament attachment in a small number of knees with Grade 4 OA. This observation is consistent with that of Mullis et al. [31], who stated that the posterior osteophyte of the MTP in varus knee OA, which is sometimes noted on the lateral knee radiograph, is intraoperatively observed at the posterolateral margin of the MTP. In addition, in the medial second quarter, there were no cases in which the anterior or posterior subchondral depression expanded over the most prominent aspect of the anterior and/or posterior cortices of the MTP. Therefore, it seems rare that osteophytes and subchondral depression affect the direct referencing

method of the MTP in knees for which medial UKA is indicated.

In both Studies I and II using MRI, the cartilage slope of the MTP was slightly smaller than the preoperative bony slope in many knees. This may be explained by the anteromedial cartilage wear on the MTP in early- to moderate-stage knee OA with a functional ACL [32, 33]. This angular error on the MRI was estimated to be 1.0° on average and less than 2.5° and is considered negligible in clinical practice because it would be virtually impossible to manually adjust the extramedullary tibial cutting guide for less than single-degree precision. A small decline in the PTS may keep the bone stock in the proximal tibia



Discussion

The results of Study I indicated that a knee with a “high” osteophyte on the medial second quarter of the MTP, which can affect the direct referencing method, is rare among knees with indications for medial UKA. Among

73 knees in Study I, only one knee with Grade 4 OA had a “high” posterior osteophyte. Furthermore, among 36 knees in Study II, no knee had a “high” osteophyte on the medial second quarter of the MTP. Observing all sagittal slices of the MRI, posterior osteophytes higher than

and reduce the risk of increased postoperative stress on the ACL [16, 20].

In Study II, the mean angle between the bony MTP and the cartilage (probe axis) MTP on intraoperative lateral knee radiography was smaller than that on preoperative sagittal MRI. In addition, the correlation between these two angles was significant but weaker than expected. The hook probe inserted into the tight joint space may be pressed into the cartilage remnants and placed close to the bony MTP, which might have made the angle on intraoperative lateral knee radiograph smaller than the angle on the preoperative sagittal MRI and made the correlation between these two angles weak.

We prospectively investigated the accuracy of the direct referencing method in Study II. The postoperative implant PTS significantly decreased by 0.5° on average compared with the preoperative bony PTS. This decline could be attributable to the difference between the bony MTP and the cartilage MTP demonstrated in Studies I and II. The RMS error between the planned and achieved PTS has been reported to be 1.6° to 1.9° with robotic assistance [34, 35]. Bush AN et al. reported that the RMS error for PTS relative to the surgeon's goals was 1.5° when an experienced surgeon manually performed medial UKA [36]. In this study, the RMS error of the PTS was 1.6° with the direct referencing method. Furthermore, a strong correlation between the preoperative bony PTS and the implant PTS was found. The accuracy of this method is considered to be equal to that of robotic-assisted surgery or surgery by an experienced high-volume surgeon.

The present study had certain limitations. First, the study population included only Japanese patients. Furthermore, the indication for medial UKA for the patients enrolled in the present study was determined by one surgeon (M.A.). Caution may be needed when the clinical application of our findings is considered in other nations and is adopted by other surgeons. Second, caution should be exercised regarding the flexibility of the arthroscopic probe. If the probe is thin and flexible, the axis of the probe can indicate a larger PTS than the preoperative bony PTS due to the bend of the probe. Third, it is rare, but there was one knee with Grade 4 OA that had posterior "high" osteophytes on the medial second quarter of the MTP. When the posterior "high" osteophyte is noted on the preoperative lateral knee radiograph, preoperative MRI or CT scan is recommended to confirm no "high" osteophyte on the medial second quarter of the MTP.

Conclusions

Cartilage remnants, osteophyte formation and subchondral bone depression do not affect the direct referencing method of the MTP, and the direct referencing method

is available in almost all knees for which medial UKA is indicated. When a posterior "high" osteophyte on a preoperative lateral knee radiograph is noted, preoperative MRI or CT scan is recommended. The accuracy of this method seems to be equal to that of robotic-assisted surgery or surgery performed by experienced high-volume surgeons, although the probe on the MTP would indicate the PTS slightly smaller than the native bony PTS.

Abbreviations

UKA: Unicompartmental knee arthroplasty; OA: Osteoarthritis; PTS: Posterior tibial slope; MTP: Medial tibial plateau; AP: Anteroposterior; MRI: Magnetic resonance imaging; ACL: Anterior cruciate ligament; FTA: Femorotibial angle; SD: Standard deviation; RMS: Root mean square.

Author contributions

All authors participated in the conception and execution of the study. MA supervised the study. MA and FA observed MRI and collected the data. SM and NS measured and collected the radiological parameters. MA, SM and AM analyzed the data. MA and FA prepared the manuscript. All authors read and approved the final manuscript.

Funding

This research did not receive any specific grants from funding agencies in the public, commercial, or nonprofit sections.

Availability of data and materials

The datasets used or analyzed in the current study are available from the corresponding author on reasonable request.

Declarations

Ethics approval and consent to participate

Approval of the institutional review board in our institute was obtained for this study (reference number 02-007).

Consent for publication

Written informed consent was obtained from the patient for publication of this study.

Competing interests

The authors declare that they have no competing interests.

Author details

¹Department of Orthopaedic Surgery, Kindai University Hospital, 377-2 Ohno-Higashi, Osaka-Sayama City, Osaka 589-8511, Japan. ²Department of Orthopaedic Surgery, Sakura-Kai Hospital, 2610-1 Handa 5, Osaka-Sayama City, Osaka 589-0011, Japan. ³Department of Orthopaedic Surgery and Rheumatology, Kindai University Nara Hospital, 1248-1 Otoda-cho, Ikoma City, Nara 630-0293, Japan.

Received: 23 March 2022 Accepted: 16 May 2022

Published online: 25 June 2022

References

- Berger RA, Meneghini RM, Jacobs JJ, Skeinop MB, Della Valle CJ, Rosenberg AG, Galante JO. Results of unicompartmental knee arthroplasty at a minimum of ten years of follow-up. *J Bone Joint Surg Am*. 2005;87:999–1006.
- Campi S, Pandit H, Hooper G, Snell D, Jenkins C, Dodd CAF, Maxwell R, Murray DW. Ten-year survival and seven-year functional results of cementless Oxford unicompartmental knee replacement: a prospective consecutive series of our first 1000 cases. *Knee*. 2018;25:1231–7.

3. Fabre-Aubrespy M, Ollivier M, Pesenti S, Parratte S, Argenson JN. Unicompartmental knee arthroplasty in patients older than 75 results in better clinical outcomes and similar survivorship compared to total knee arthroplasty. A matched controlled study. *J Arthroplasty*. 2016;31:2668–71.
4. Sirman H, Kamath AF, Carrillo N, Harmsen WS, Pagnano MW, Sierra RJ. Unicompartmental knee arthroplasty vs total knee arthroplasty for medial compartment arthritis in patients older than 75 years: comparable reoperation, revision, and complication rates. *J Arthroplasty*. 2017;32:1792–7.
5. Burn E, Sanchez-Santos MT, Pandit HG, Hamilton TW, Liddle AD, Murray DW, Pinedo-Villanueva R. Ten-year patient-reported outcomes following total and minimally invasive unicompartmental knee arthroplasty: a propensity score-matched cohort analysis. *Knee Surg Sports Traumatol Arthrosc*. 2018;26:1455–64.
6. Lyons MC, MacDonald SJ, Somerville LE, Naudie DD, McCalden RW. Unicompartmental versus total knee arthroplasty database analysis: is there a winner? *Clin Orthop Relat Res*. 2012;470:84–90.
7. Noticewala MS, Geller JA, Lee JH, Macaulay W. Unicompartmental knee arthroplasty relieves pain and improves function more than total knee arthroplasty. *J Arthroplasty*. 2012;27:99–105.
8. Bellemans J, Colyn W, Vandenuecker H, Victor J. The Chitranjan Ranawat award: is neutral mechanical alignment normal for all patients? The concept of constitutional varus. *Clin Orthop Relat Res*. 2012;470:45–53.
9. Deschamps G, Chol C. Fixed-bearing unicompartmental knee arthroplasty. Patients' selection and operative technique. *Orthop Traumatol Surg Res*. 2011;97:648–61.
10. Heyse TJ, El-Zayat BF, De Corte R, Chevalier Y, Scheys L, Innocenti B, Fuchs-Winkelmann S, Labey L. UKA closely preserves natural knee kinematics in vitro. *Knee Surg Sports Traumatol Arthrosc*. 2014;22:1902–10.
11. Vasso M, Del Regno C, D'Amelio A, Viggiano D, Corona K, Schiavone PA. Minor varus alignment provides better results than neutral alignment in medial UKA. *Knee*. 2015;22:117–21.
12. Barbadoro P, Ensigni A, Leardini A, D'Amato M, Feliciangeli A, Timoncini A, Amadei F, Belvedere C, Giannini S. Tibial component alignment and risk of loosening in unicompartmental knee arthroplasty: a radiographic and radiostereometric study. *Knee Surg Sports Traumatol Arthrosc*. 2014;22:3157–62.
13. Bourne RB, Chesworth BM, Davis AM, Mahomed NN, Charron KD. Patient satisfaction after total knee arthroplasty: who is satisfied and who is not? *Clin Orthop Relat Res*. 2010;468:57–63.
14. Dai X, Fang J, Jiang L, Xiong Y, Zhang M, Zhu S. How does the inclination of the tibial component matter? A three-dimensional finite element analysis of medial mobile-bearing unicompartmental arthroplasty. *Knee*. 2018;25:434–44.
15. Franz A, Boese CK, Matthies A, Leffler J, Ries C. Mid-term clinical outcome and reconstruction of posterior tibial slope after UKA. *J Knee Surg*. 2019;32:468–74.
16. Hernigou P, Deschamps G. Posterior slope of the tibial implant and the outcome of unicompartmental knee arthroplasty. *J Bone Joint Surg Am*. 2004;86:506–11.
17. Kang K-T, Park J-H, Koh Y-G, Shin J, Park KK. Biomechanical effects of posterior tibial slope on unicompartmental knee arthroplasty using finite element analysis. *Biomed Mater Eng*. 2019;30:133–44.
18. Sekiguchi K, Nakamura S, Kuriyama S, Nishitani K, Ito H, Tanaka Y, Watanaabe M, Matsuda S. Effect of tibial component alignment on knee kinematics and ligament tension in medial unicompartmental knee arthroplasty. *Bone Joint Res*. 2019;8:126–35.
19. Suzuki T, Ryu K, Kojima K, Oikawa H, Saito S, Nagaoka M. The effect of posterior tibial slope on joint gap and range of knee motion in mobile-bearing unicompartmental knee arthroplasty. *J Arthroplasty*. 2019;34:2909–13.
20. Plancher KD, Shanmugam JP, Brite JE, Briggs KK, Petterson SC. Relevance of the tibial slope on functional outcomes in ACL-deficient and ACL intact fixed-bearing medial unicompartmental knee arthroplasty. *J Arthroplasty*. 2021;36:3123–30.
21. Matsuda S, Miura H, Nagamine R, Urabe K, Ikenoue Y, Okazaki K, Iwamoto Y. Posterior tibial slope in the normal and varus knee. *Am J Knee Surg*. 1999;12:165–8.
22. Nunley RM, Nam D, Johnson SR, Barnes CL. Extreme variability in posterior slope of the proximal tibia: measurements on 2395 CT scans of patients undergoing UKA? *J Arthroplasty*. 2014;29:1677–80.
23. Takayama K, Matsumoto T, Muratsu H, Ishida K, Araki D, Matsushita T, Kuroda R, Kurosaka M. The influence of posterior tibial slope changes on joint gap and range of motion in unicompartmental knee arthroplasty. *Knee*. 2016;23:517–22.
24. Weber P, Woiczinski M, Steinbrück A, Schömidutz F, Niethammer T, Schröder C, Jansson V, Müller PE. Increase in the tibial slope in unicompartmental knee replacement: analysis of the effect on the kinematics and ligaments in a weight-bearing finite element model. *Biomed Res Int*. 2018;2018:8743604.
25. Mori S, Akagi M, Moritake A, Tsukamoto I, Yamagishi K, Inoue S, Nakagawa K, Togawa D. The medial tibial plateau can be used as a direct anatomical reference for the posterior tibial slope in medial unicompartmental knee arthroplasty. *J Knee Surg*. 2021. Online ahead of print.
26. Kellgren JH, Lawrence JS. Radiological assessment of osteo-arthrosis. *Ann Rheum Dis*. 1957;16:494–502.
27. Akagi M, Oh M, Nonaka T, Tsujimoto H, Asano T, Hamanishi C. An anteroposterior axis of the tibia for total knee arthroplasty. *Clin Orthop Relat Res*. 2004;420:213–9.
28. Tsukamoto I, Akagi M, Mori S, Inoue S, Asada S, Matsumura F. Anteroposterior rotational references of the tibia for medial unicompartmental knee arthroplasty in Japanese patients. *J Arthroplasty*. 2017;32:3169–75.
29. Peterfy CG, Guermazi A, Zaim S, Tirman PF, Miaux Y, White D, Kathari M, Lu Y, Fye K, Zhao S, Genant HK. Whole-Organ Magnetic Resonance Imaging Score (WORMS) of the knee in osteoarthritis. *Osteoarthr Cartil*. 2004;12:177–90.
30. Haddad B, Konan S, Mannan K, Scott G. Evaluation of the posterior tibial slope on MR images in different population groups using the tibial proximal anatomical axis. *Acta Orthop Belg*. 2012;78:757–63.
31. Mullis BH, Karas SG, Kelley SS. Characterization of a consistent radiographic finding in chronic anterior cruciate ligament deficiency: the posteromedial osteophyte. *Am J Orthop*. 2007;36:494–7.
32. Mullaji AB, Marwar SV, Luthra M. Tibial articular cartilage wear in varus osteoarthritic knees: correlation with anterior cruciate ligament integrity and severity of deformity. *J Arthroplasty*. 2008;23:128–35.
33. White SH, Ludkowski PF, Goodfellow JW. Anteromedial osteoarthritis of the knee. *J Bone Joint Surg Br*. 1991;73:582–6.
34. Bell SW, Anthony I, Jones B, MacLean A, Rowe P, Blyth M. Improved accuracy of component positioning with robotic-assisted unicompartmental knee arthroplasty: data from a prospective, randomized controlled study. *J Bone Joint Surg Am*. 2016;98:627–35.
35. Lonner JH, John TK, Conditt MA. Robotic arm-assisted UKA improves tibial component alignment. A pilot study. *Clin Orthop Relat Res*. 2010;468:141–6.
36. Bush AN, Zieme-Davis M, Deckard ER, Meneghini RM. An experienced surgeon can meet or exceed robotic accuracy in manual unicompartmental knee arthroplasty. *J Bone Joint Surg Am*. 2019;101:1479–84.

Publisher's Note

Springer Nature remains neutral with regard to jurisdictional claims in published maps and institutional affiliations.

Ready to submit your research? Choose BMC and benefit from:

- fast, convenient online submission
- thorough peer review by experienced researchers in your field
- rapid publication on acceptance
- support for research data, including large and complex data types
- gold Open Access which fosters wider collaboration and increased citations
- maximum visibility for your research: over 100M website views per year

At BMC, research is always in progress.

Learn more biomedcentral.com/submissions

